Glenoid bone loss reconstruction in TSA revision

Jean Kany

Shoulder department

Clinique de l' Union

Toulouse

FRANCE

ÉPAULE

TCULCUSE



Katowice, Poland, December 2015

Conflict of Interest

Jean Kany:

FH Orthopedics (Arrow designer)

11000/year Shoulder Prosthesis France

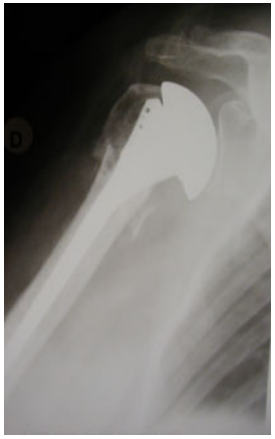

5500 Anatomical

- 2500: "Hemi"
- 3000: TSA

Hasan SS, (2002) J Should Elb Surg 2(11):431–441
Torchia ME, (1997). J Should Elb Surg 6:495–505
Sperling JW, (2004) J Surg 13:604–613

Survey: 80% after 15 years

TSA Complications: 10% to 16%

- *M Wirth et al JBJS(am) 1996* — *FU 3.5 Years*
  1459 prosthesis / 204 compl — 14%
- *Walch et Aequalis Group 2000* — *FU 3.6 Years*
  766 prosthesis / 93 compl — 13%
- *Boshali et al JBJS(am) 2006* — *FU 5 Years*
  2810 prosthesis / 414 compl — 14,7%
- *Chin PY et al JSES 2006* — *FU 5 years*
  431 prosthesis / 53 compl — 12%

Causes of TSA Revision

1. Glenoid component loosening+++
2. Instability
3. Hemi failure after trauma
4. Rotator Cuff Tear
5. Infection

Lehmann L, (2010) Int Orthop 34(8):1219–1225
Aldinger PR, (2010) Int Orthop 34(4):517–524
Sajadi KR, (2009) J Should Elb Surg 19(2):308–313

Glenoid Component Loosening

Fréquent (RLL >80%)

- Lazarus MD, (2002) J Bone Joint Surg Am 84-A:1174–1182

Without Symptoms? (2-5% révisions)

- Neer CS (1990) In: Neer R (ed). Saunders, Philadelphia, pp 220–260
- Rodosky MW, (2002) J Shoulder Elbow Surg 5:231–248
- Brems (1400 prostheses) 2,9 %
- Cofield (1459 prostheses) 1,9 %

Main Cause of Revisions++++

- Matsen FA 3rd, (2007) J Shoulder Elbow Surg 16(5 Suppl):S241–S247
- Bohsali KI, (2006) J Bone Joint Surg Am 88:2279–2292

Glenoid Radiolucent Lines

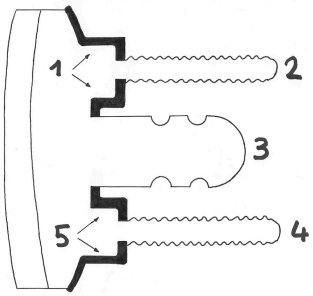

Sperling JW, Cofield RH, O'Driscoll SW, Torchia ME, Rowland CM (2000)
Radiographic assessment of ingrowth total shoulder arthroplasty.
J Shoulder Elbow Surg 9:507–513

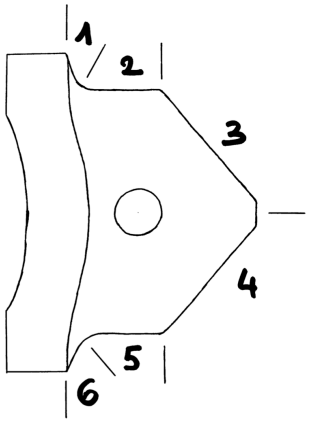

Mileti J, Boardman ND III, Sperling JW, Cofield RH, Torchia ME, O'Driscoll SW, Charles M, Rowland CM (2004)
Radiographic analysis of polyethylene glenoid components using modern cementing techniques.
J Shoulder Elbow Surg 13:492–498



Molé D, Roche O, Riand N, Lévigne C, Walch G (1999)
Cemented glenoid component: results in osteoarthritis and rheumatoid arthritis.
In: Walch G, Boileau P (eds) Shoulder arthroplasty. Springer, Berlin, pp 163–171

Glenoid Radiolucent Lines

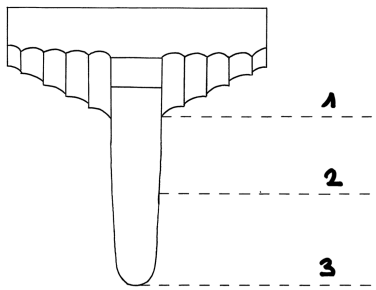

Wilde A, Borden LS, Brems JJ (1984)
Experience with Neer total shoulder replacement.
In: Bateman JE, Welsch RP (eds) Surgery of the shoulder. B.C. Decker Inc, Philadelphia, pp 224–228

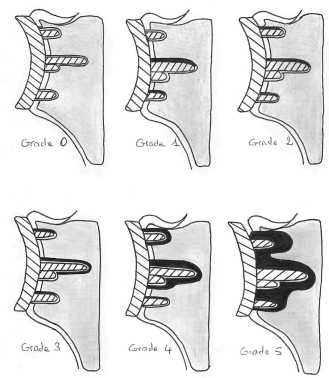

Lazarus MD, Jensen KL, Southworth C, Matsen FA III (2002)
The radiographic evaluation of keeled and pegged glenoid component insertion.
J Bone Joint Surg Am 84:1174–1182

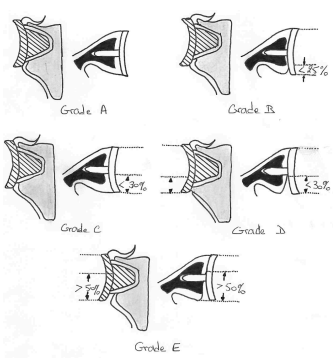

Barwood S, Setter KJ, Blaine TA, Bigliani LU (2008)
The incidence of early radiolucencies about a pegged glenoid component using cement pressurization.
J Shoulder Elbow Surg 17:703–708

68 y/o, man

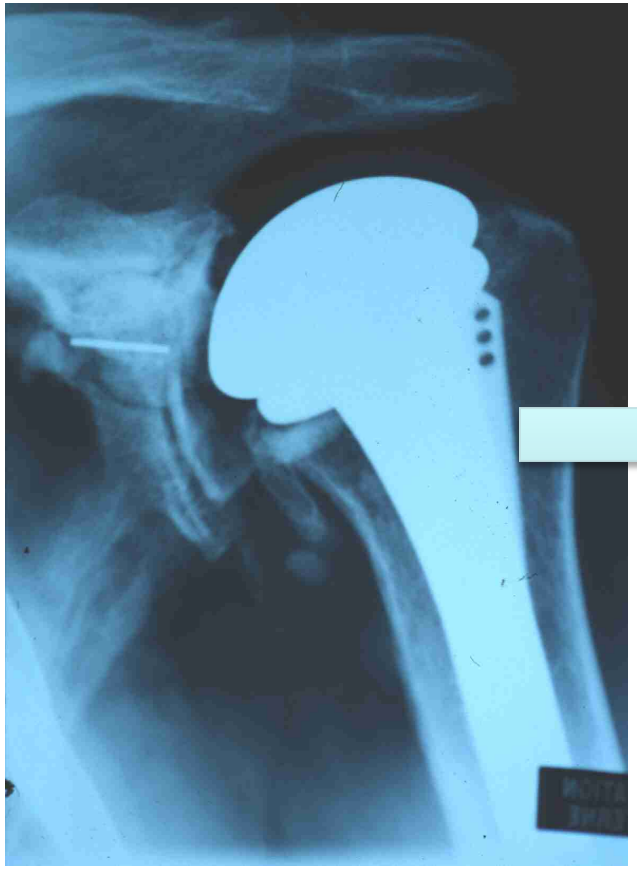

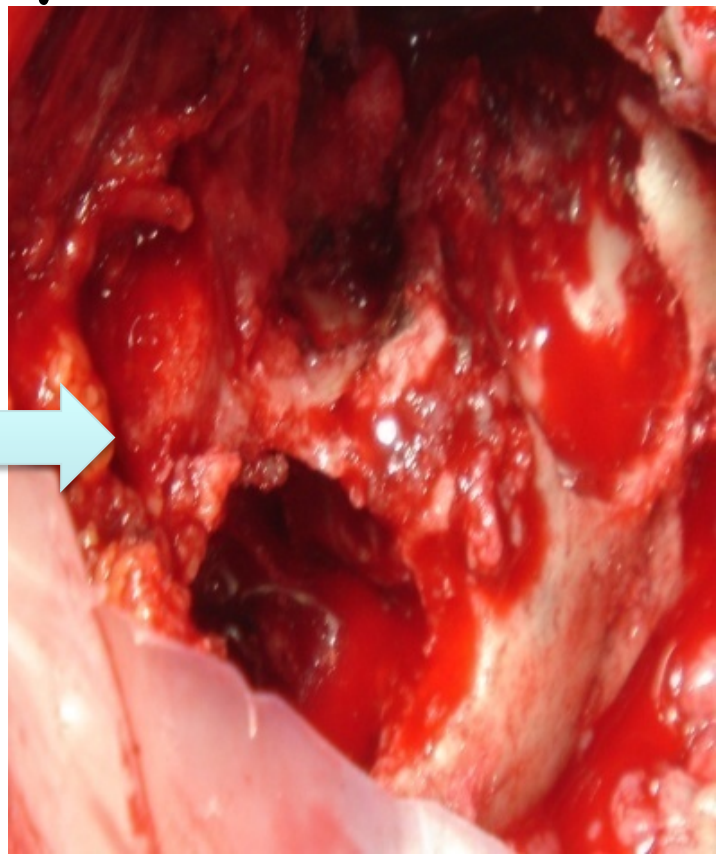

Options to Deal with A Glenoid Loosening?

Glenoid reconstruction: Do you also feel alone?



How to Manage a Challenging Glenoid ?

- To correct the retroversion (horizontal)
- To correct the inclination (vertical)
- Anatomic position of the articular line

  Lateral offset ++

  Good balance of the muscles

Depend on Rotator Cuff++++

Pre op Planning
Xrays CT Scan+++ 3D

- *State of soft tissue:*

  subscapularis

  postero superior cuff

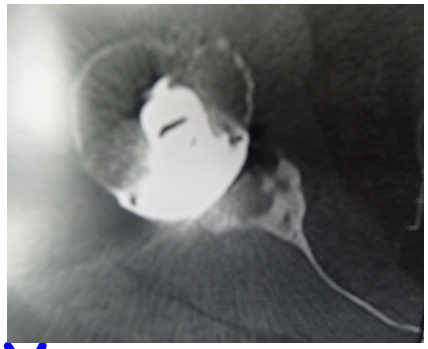

- State of glenoid bone deficiency

  type and size of glenoid bone loss

after removing PE component and cement

DIFFICULT pre operatively
Glenoid bone loss underestimated +++

Glenoid Bone Loss Classification after Glenoid Component removal

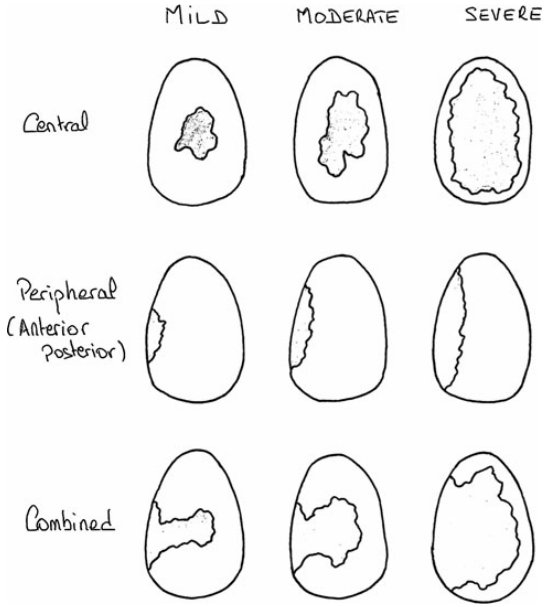

Antuna SA, Sperling JW, Cofield RH, Rowland CM (2001)
Glenoid revision surgery after total shoulder arthroplasty.
J Shoulder Elbow Surg 10:217–224

Glenoid Bone Loss Classification after Glenoid Component removal

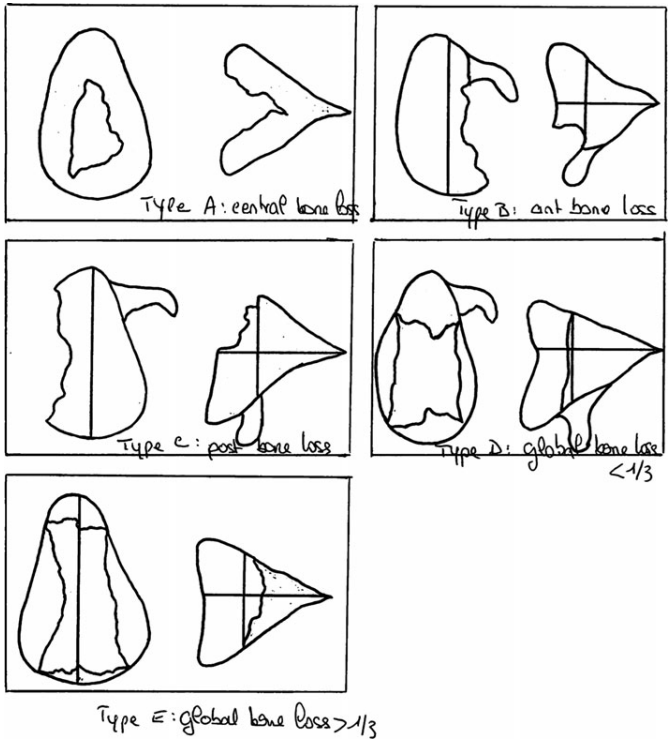

Katz D, Sauzière Ph, Valenti Ph, Kany J (2012) The case for the metal-backed glenoid design in total anatomical shoulder arthroplasty. Eur J Orthop Surg Traumatol 22:9–16

Revision of Glenoid Loosening

Soft tissue is Functionnal → Anatomic TSA + MB + bone graft

Soft tissue is Deficient → RTSA + MB long post +bone graft

Litterature reported useful and excellent results of RSA

Litterature Review

- Revision with new glenoid PE
  cemented + Bone

Bonneviale et al Nice Shoulder course 2010

FU 74 months failure was 67%

- Revision with a RSA

Melis et al JSES 2012

FU 47 months 37 cases 86% Satisfied

Litterature Review

Better with a glenoid component

- *Antuna, Sperling, Cofield, Rowland. JSES 2001*
- *Cofield RH, Edgerton BC. Instr Course Lect 1990*
- *Rodosky MW, Weinstein DM, Pollock RG, et al. JSES 1995*

- Glenoid corticocancellous bone grafting after glenoid component removal in the treatment of glenoid loosening

  Neyton et al JSES 2006

  FU 30 months 9 patients 5 satisfied

Options to Deal with A Glenoid Loosening?

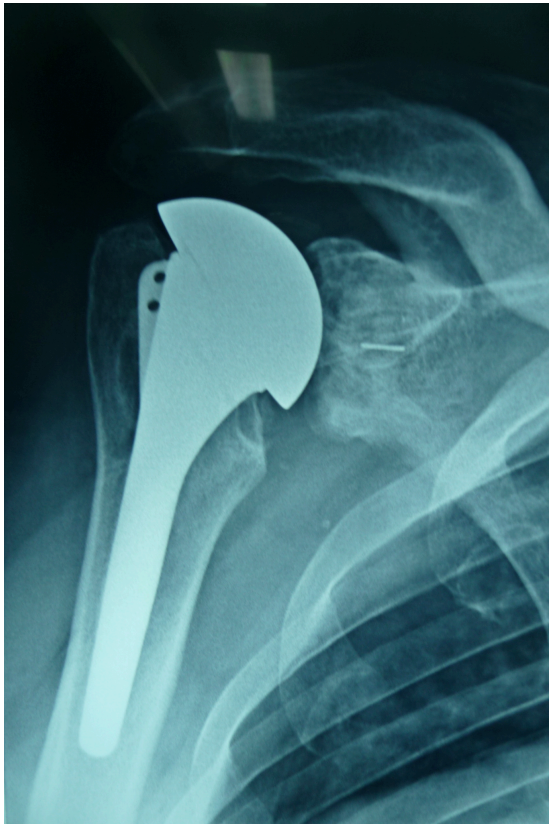

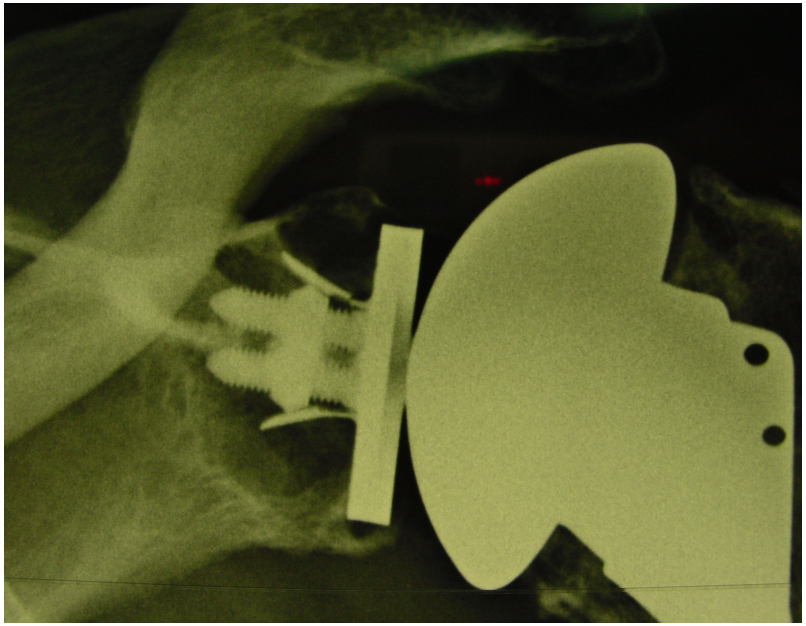

The cuff is functionnal

Bone deficiency !!!

→ Anatomic shoulder arthroplasty

MB long post

→ + bone graft

Litterature Long post base plate Rare !!!!

- T Norris et al 2007

Management of Glenoid Bone Defects in Revision Shoulder Arthroplasty: A New Application of the Reverse Total Shoulder Prosthesis

Techniques in Shoulder and Elbow Surgery 8(1):37–46, 2007

Cylinder

Big

Flat base plate

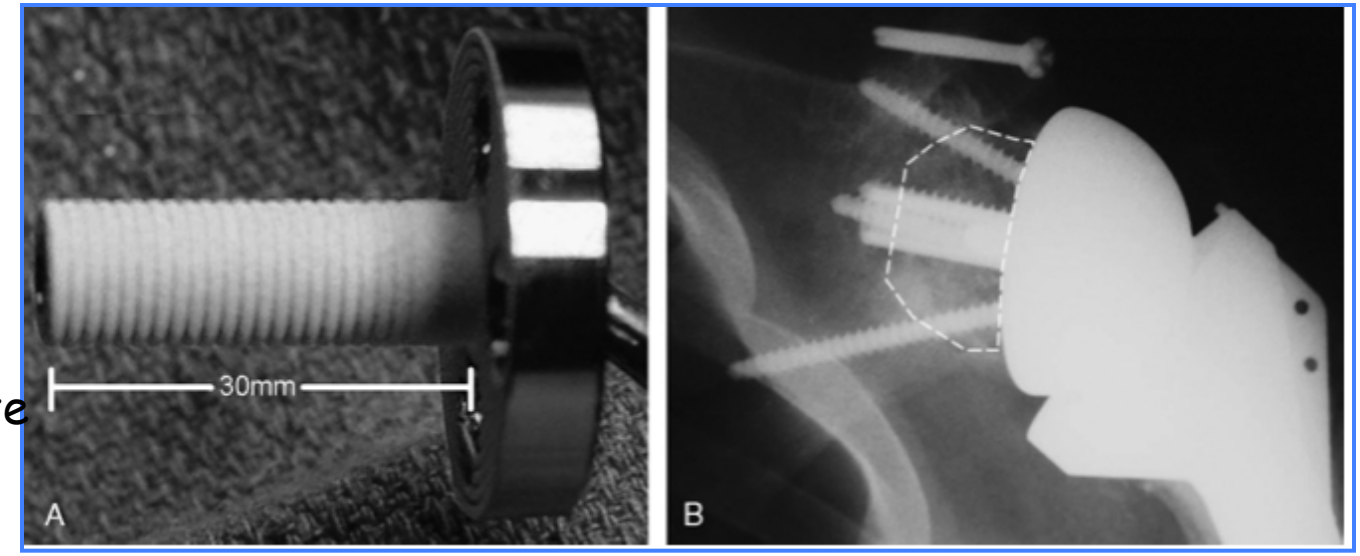

Arrow universal system
Long post base plate

Anatomic

Reverse



A long post Base Plate 40mm

- Fixation into the native bone

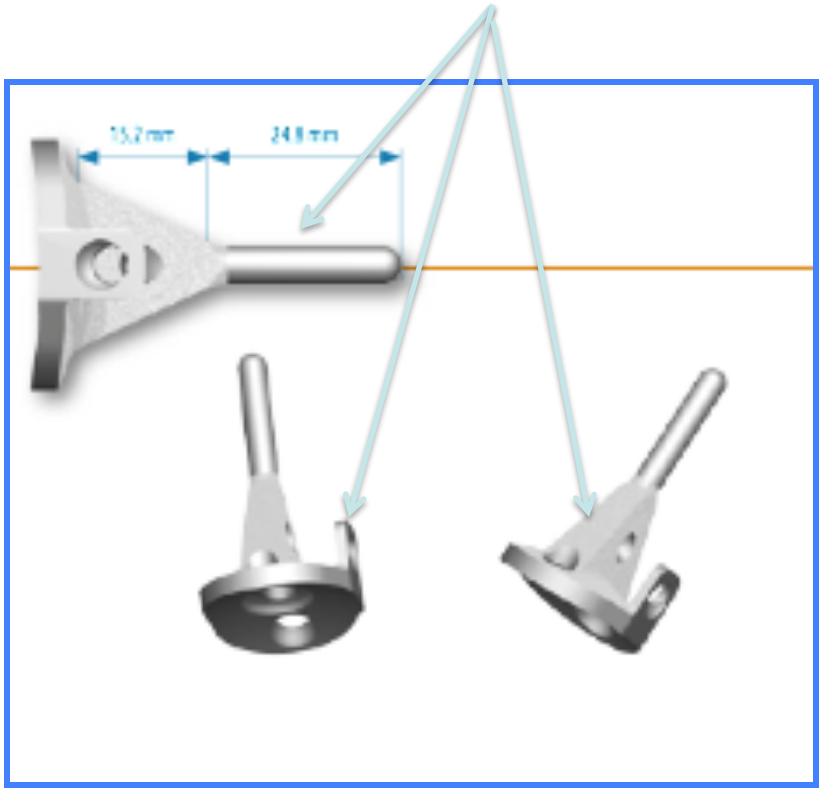

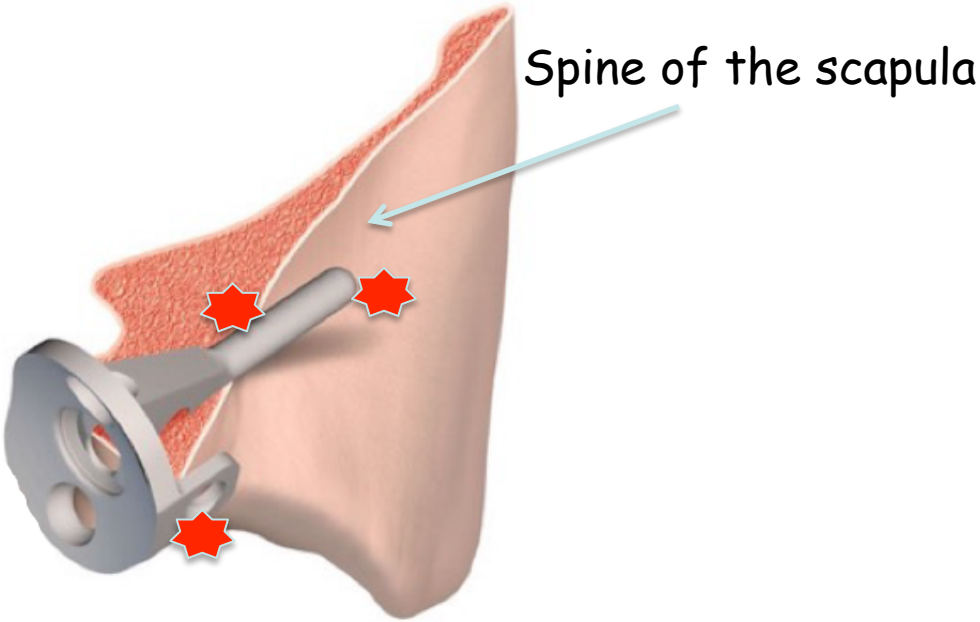





Special Design

- 3 points of fixation
- Improve press fit
- Bone graft fixation

Biomechanics (JD Werthel)



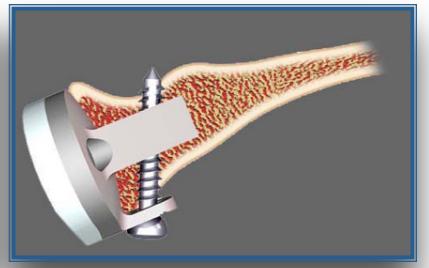



- Different RSA systems implanted into composite synthetic bone models (properties = glenoid bone).
- Custom-made extensometer under superior end glenoid plate implant.
- Cyclic load :compressive load —> simulate rehabilitative loads on implant over a 3-month period.
- Critical period : micromotion< 150 µm for bone ingrowth to occur.

(I) Delta III
(II) Arrow without AP screw
(III) Arrow with AP screw
(IV) Arrow small keel without AP screw
(V) Arrow long peg without AP screw
(VI) Arrow long peg with AP screw
(VII) Standard Arrow with 10° inferior tilt







Results

Micromotion lowest in condition:

VII: 81.4 µm range ; 51-108.7 µm) STANDARD INFERIOR TILT
V : 84.67 µm (range ; 62.5-125 µm) LONG PEG NO AP SCREW
VI : 88.17 µm (range ; 84-94 µm). LONG PEG AP SCREW

Condition II : micromotion of 90.3 µm (range, 73.4-118.9 µm)
Condition IV: micromotion of 92.03 µm (79.4-115.4 µm).

Worse results for Arrow :
condition III (ARROW Standard AP SCREW) :140.73 µm (90-198.9 µm)

Condition I (DELTA III) chr162.37 µm (85.8-203.8µm)

Surgical technique with a MB +long post (40mm)

- Into the spine of the scapula
- Can perforate the cortical bone

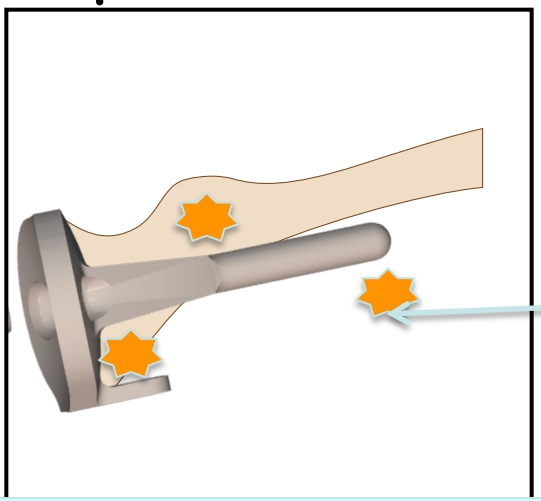

Counterpressure
to the cortical bone

The base plate should have a primary stability before to put bone graft. +++

This is the main criteria to continue the glenoid bone reconstruction

Surgical technique with a MB +long post (40mm)

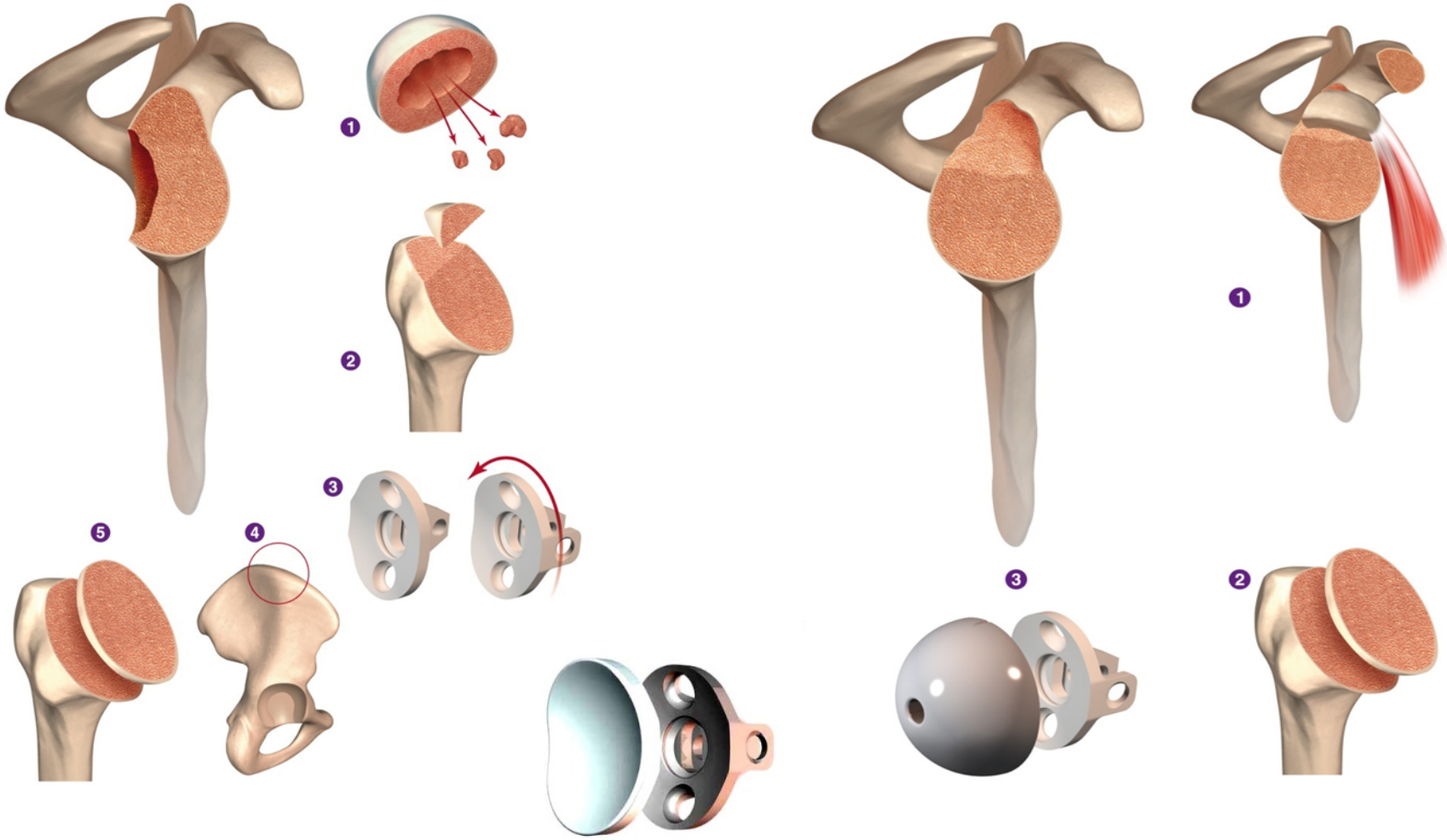

Allograft / Synthetic Graft

Advantages of a Long Peg MB

Good press fit
even no glenoid wall

Stabilisation of a bone graft

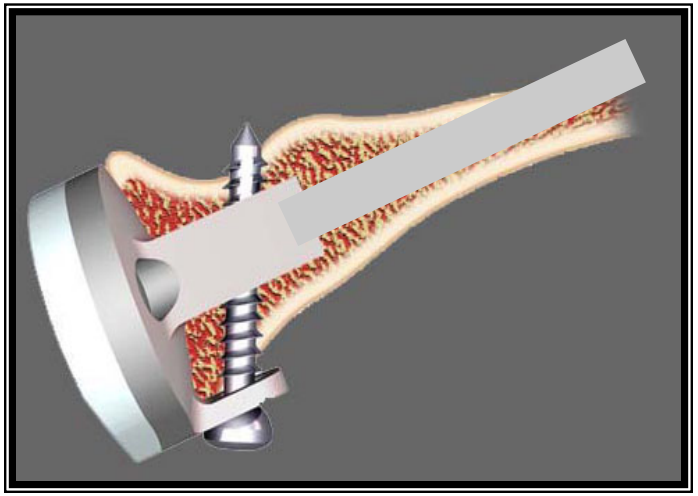

Discussion Versatil MB

- Disputed idea since Neer (Mark 2) 1978

- Cofield MB, the English Mac Nab, the Roper-Day prosthesis, the Kirschner II-C, the Burkead MB

- Aequalis



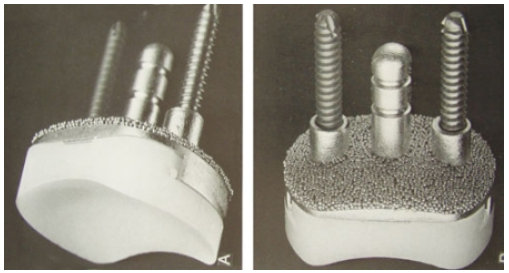

Boileau P, (2002) J Shoulder Elbow Surg 11:351–359

Metal Back Glenoid Component?

1/ Interface PE/MB

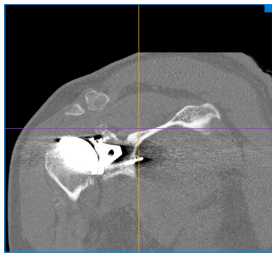



Dismentling (1 case)

2/ Thickness MB+PE: +2.5 mm ?

Subscap rupture? (2 cases)

3/ Loosening?

Rare

Jean Kany. Glenoid or not glenoid component in primary osteoarthritis. Eur J Orthop Surg Traumatol. 2012 Nov 30

Katz DC, Sauzieres P, Kany PVJ. The case for the metal-backed glenoid design in total anatomical shoulder arthroplasty. Eur J Orthop Surg Traumatol. 2012 Dec 17;22:9–16.

Materiel n =10 cases

Ph Valenti et al Arch Orthop Trauma Surg 2014 apr 12

- Retrospective review
- Operated Sept 2007 to January 2010
- 6 women / 4 men
- Mean age 64 years old(46-83)
- Previous glenoid Component:

  7 PE cemented

  3 MB in growth
- Mean delay for revision :

  70 months (25-135)

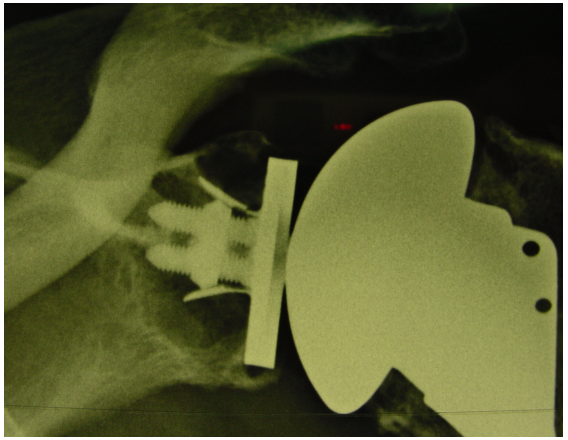

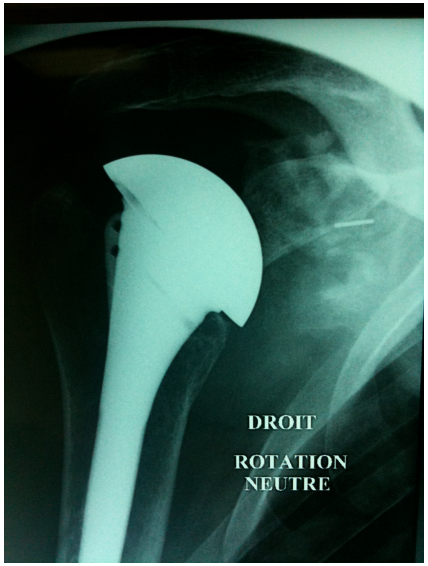

Materiel n=10 cases

- Patients included:

  Isolated Glenoid loosening

  No Subscapularis lesion / No RCT

  No Instability

- Patients excluded:

  Revision with RSA / Isolated bone graft

  Glenoid removal without reimplantation

  Infection

  Irreparable Cuff

Glenoid reconstruction

Iliac crest bone Graft	6
Synthetic bone	2
Both	2

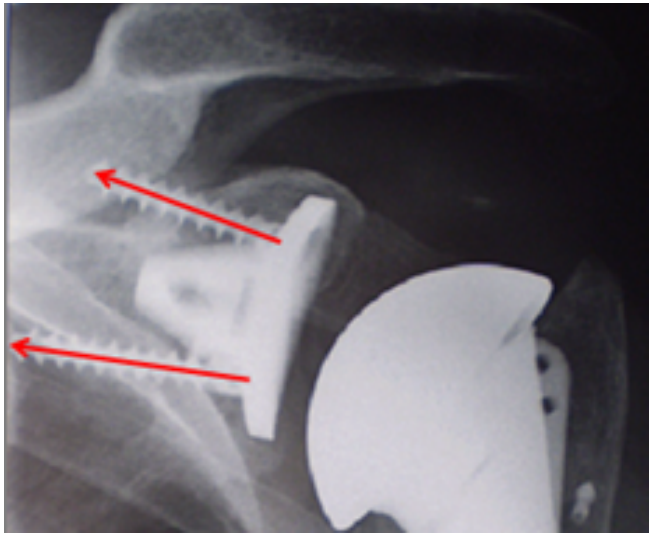

MB Keel /ant lug

MB+ AP screw

MB +long peg

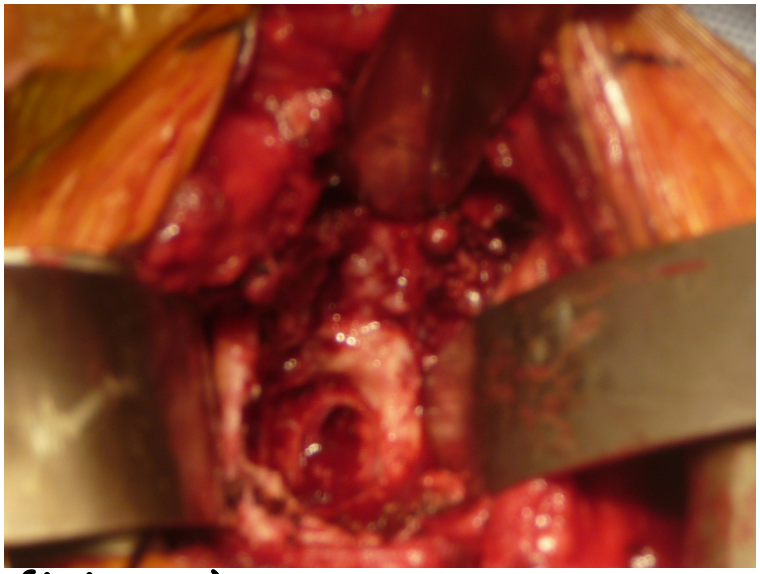

TSA with cemented glenoid PE Peg
Revision after 5 years
Glenoid bone loss Type B
(anterior and medial glenoid bone deficiency)

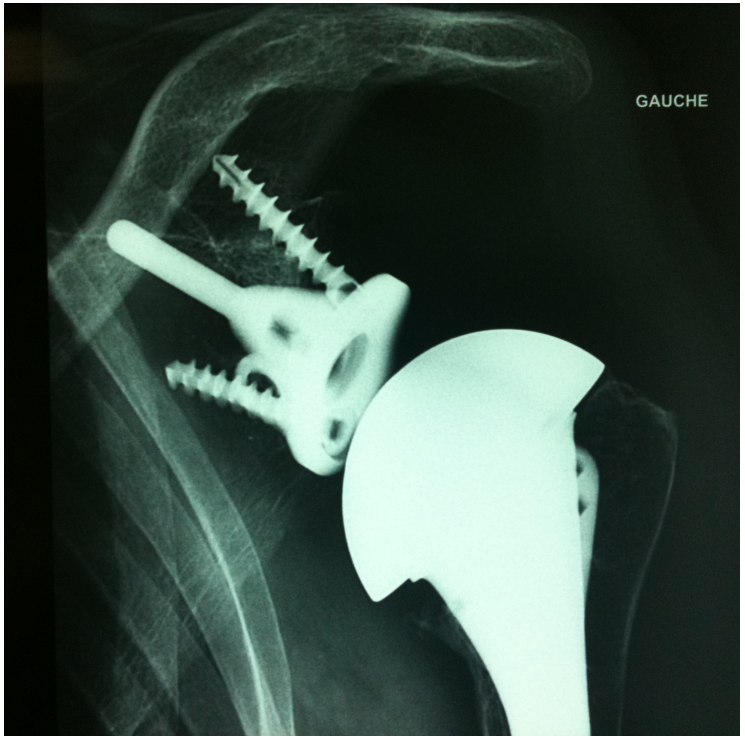
GAUCHE

GAUCHE

Results n=10 FU > 2 years p<0,001

	CONSTANT	VAS (PAIN)	SST
PRE OP	39,4	5,1	3,4
POST OP	71	0,6	7,9
GAIN	31,6	4,5	4,5

7 very satisfied 3 satisfied

Results n=10 P< 0,001

	PAIN	AAE°	ER1°	ER2°	IR pts
PRE OP	5	118	34	43	4.8
POST OP	13.7	149	47	66	6.8
GAIN	8.7	31	13	23	2

Take Home messages
Glenoid compromised !!!

- Special design of the glenoid component
- Base plate with a long post
- Correction Horizontal plane bone graft
  Vertical plane
- Plateform system+++

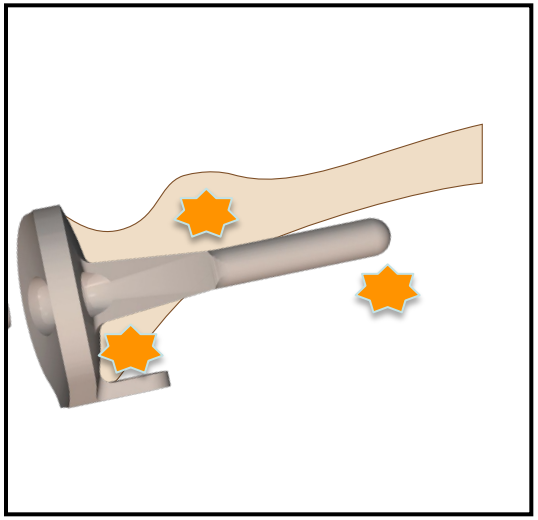

Take Home messages
Glenoid compromised !!!

Be ready before jumping…Platform system+++
And
Stay Modest…

Long post base plate

- Can extend limits RSA ?
- Can decrease too high rate of complications ?

- Improvment of prosthetic design
- Surgeon with a Greater experience
- Optimization fixation baseplate
  (spine fixation, Inf tilt ++)

But Be aware
and stay modest +++

Thank you

ÉPAULE
TCULCUSE

Broadcast

Vims

A le révision on retrouve fréquemment:

1. une perte de substance osseuse (glène)
2. Une destruction importante de la coiffe
3. Rarement le descellement de la tige est en cause

Il est proposé la mise en place:

- d' une prothèse inversée
- avec reconstruction osseuse

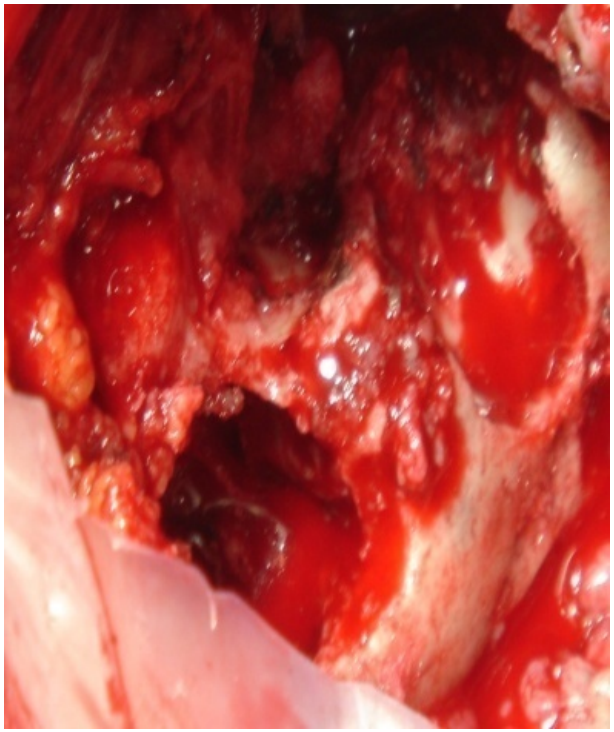

Flury MP, (2011) Int Orthop 35(1):53–60

La révision impose souvent:

volet diaphysaire (sarcophage)

Risque Fracture humérale
20 à 24%

Van Thiel GS, (2011) J Should Elb Surg 20(8): 1248–1254

Wall B, (2007) J Bone Joint Surg Am 89:1476–1485

Special design

AP or PA screw to fix the bone graft

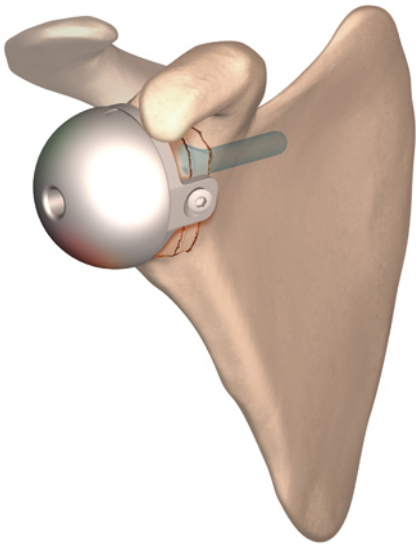

Anterior bone graft

Posterior bone graft

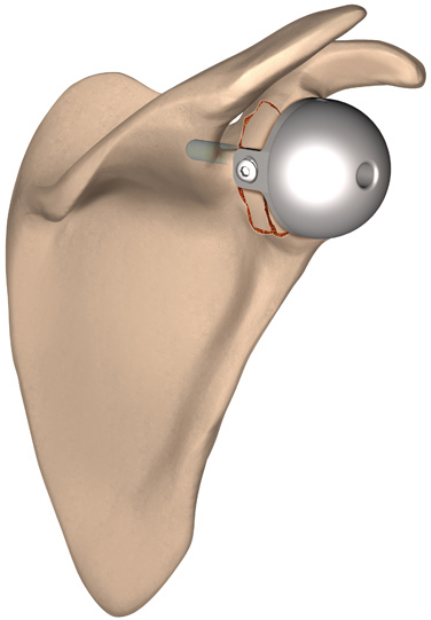

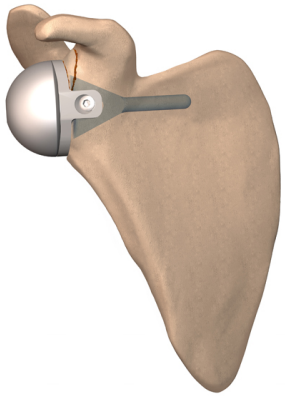

Superior bone graft

How to treat glenoid B2 and C? The debate

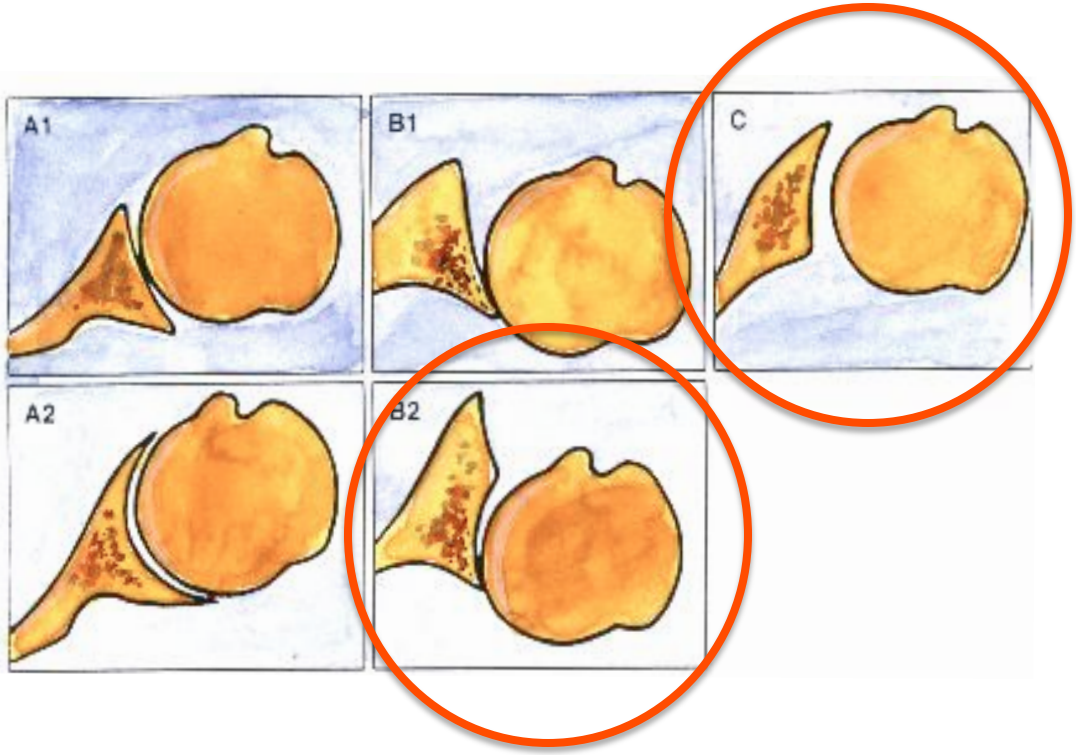

Jean Kany
Shoulder department
Clinique de l' Union
Toulouse
FRANCE

Gilles Walch, Luc Favard, Laurent Lafosse, Peter Habermeyer

Friedman angle

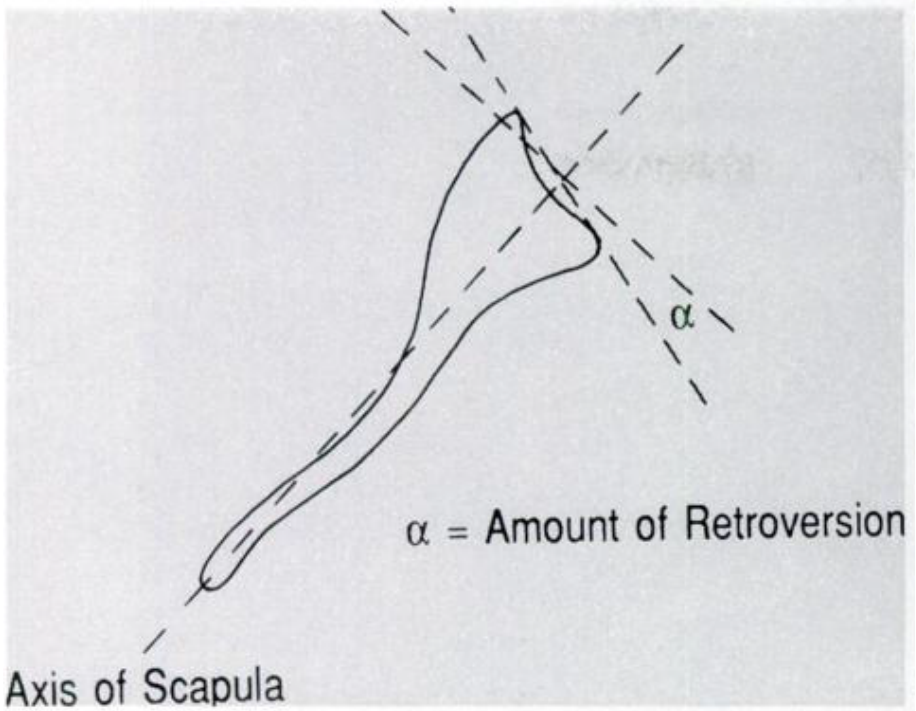

Friedman RJ, Hawthorne KB, Genez BM
The use of computerized tomography in the measurment of glenoid version.
J Bone Joint Surg 1992; 74-A: 1032-37

Index of Humeral Head Subluxation

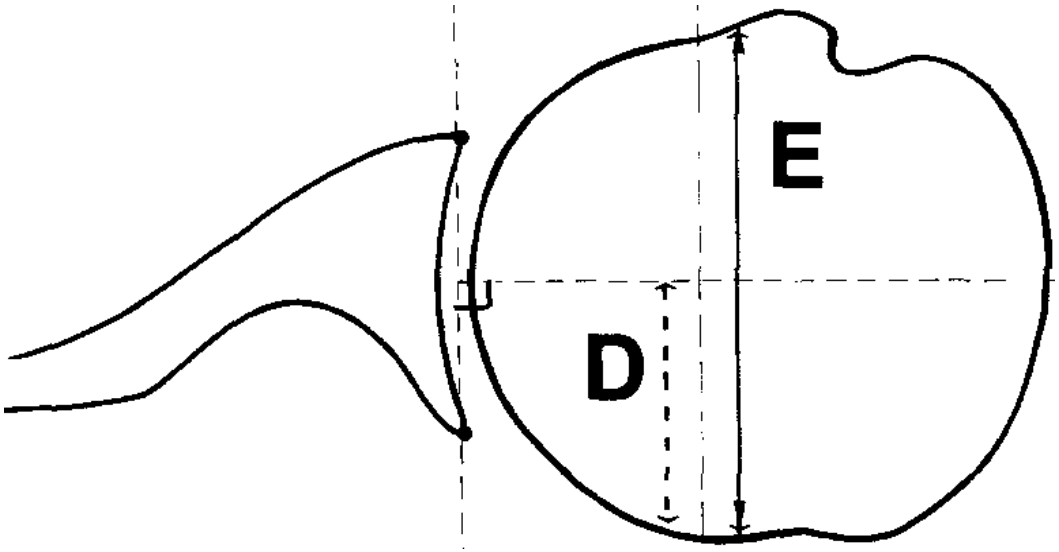

Posterior HH subluxation:
Index D/E > 55%

Papilion JA, Shall LM.
Fluoroscopic evaluation for subtle shoulder instability.
Am J Sports Med. 1992 Sep; 20(5):548–552.

Type B2 Glenoid

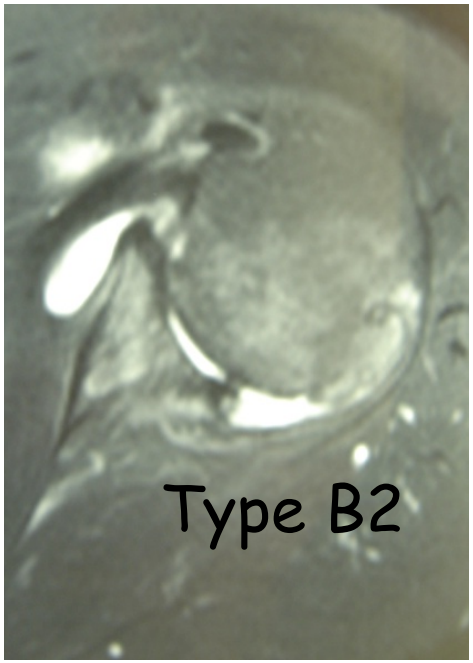

« … posterior HH subluxation… »

« … typical biconcave aspect… »

« … excessive glenoid retroversion (23,4°) »

Type C Glenoid



>25°

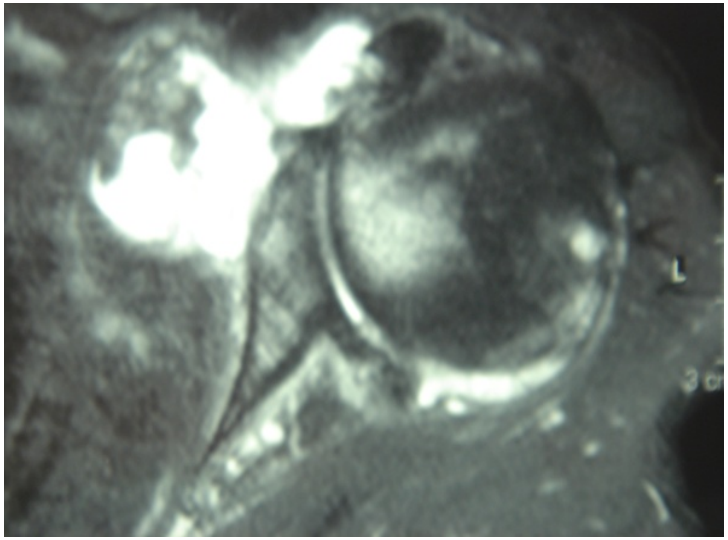

Type C

« … clearly congenital… »

« …Index of subluxation ranged from 35% to 75% (average 55%).... »

How often do these situations occur ?

1998: B2+C= 32.5%

1999: B2+C= 24%

- Walch G, Boulahia A, Boileau P, Kempf JF. Primary glenohumeral osteoarthritis: clinical and radiographic classification. The Aequalis Group
. Acta Orthop Belg. 1998

- 151 cases of primary glenohumeral osteoarthritis
Type A : 53.5% (A1: 39.5%, A2: 14%)
Type B : 39.5% (B1: 12%, B2: 27.5%)
Type C : 5%

- Walch G, Badet R, Boulahia A, Khoury A. Morphologic study of the glenoid in primary glenohumeral osteoarthritis. J Arthroplasty. 1999; 14:756-60.

- 113 cases of primary glenohumeral osteoarthritis
Type A : 59% (A1: 43%, A2: 16%
Type B : 32% (B1: 17%, B2: 15%)
Type C : 9%

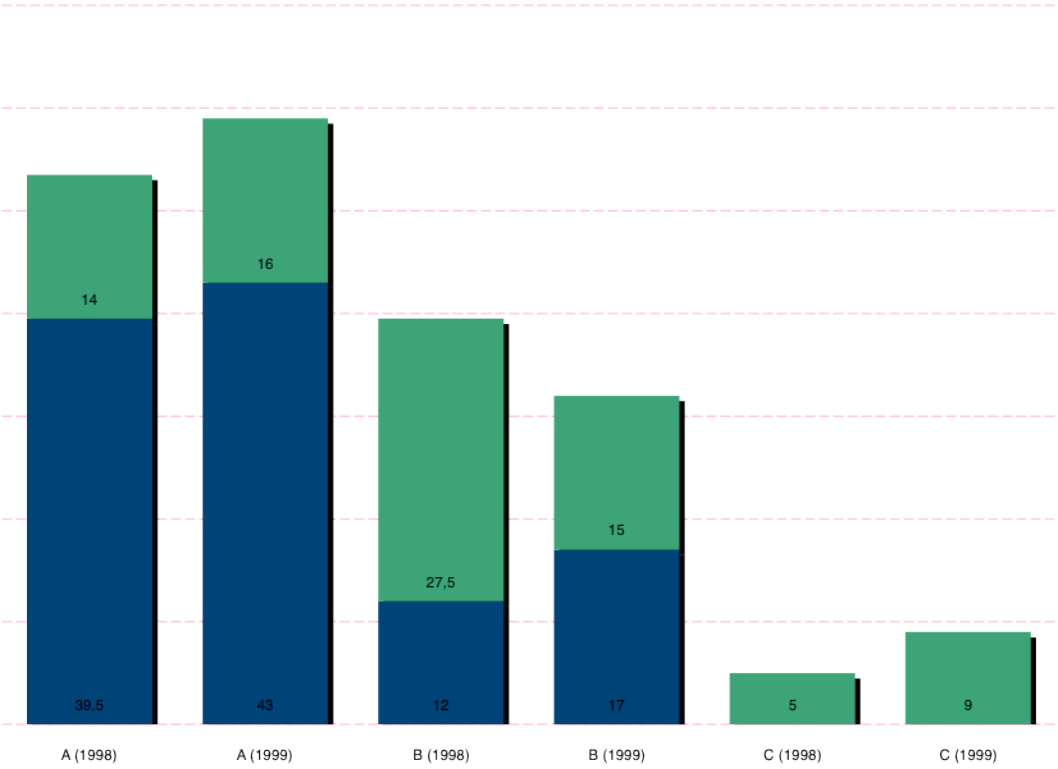

1st question:

Frequency?

Gilles Walch: B2 (17-27.5%) + C (5-9%) = 24-32.5%

1. More frequent?
2. Equal?
3. Less frequent?

What about vertical plane?

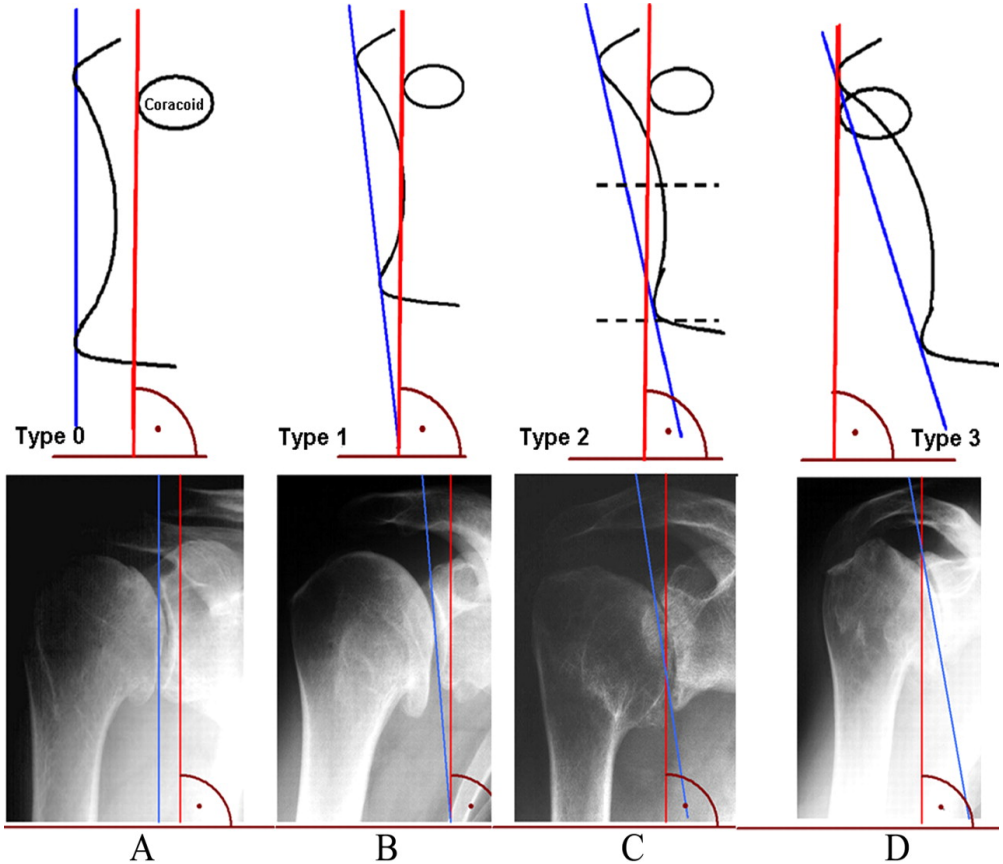

Habermeyer P, Magosch P, Lichtenberg S.
Three-Dimensional GlenoidDeformity in Patientswith Osteoarthritis:A Radiographic Analysis.
J Bone Joint Surg 2006 (88A); 6: 1301-7.

2nd question:

Vertical erosion?

1/ Does it matter?

2/ Is there any association with glenoid B2 or C?

3rd question:

In routine

Which exam (s) do you need?

1. Plain X-rays?
2. CT scan?
3. Contrast-CT scan?
4. MRI?
5. Contrast MRI?
6. Others?

How do you manage glenoid Type B2 and type C?

1. Same technique?
2. Same indication?

Approach?

1. Delto-pectoral?
2. Superior?
3. Posterior?

Which treatment?

Why?

1. Hemi?
2. TSA with cemented glenoid?
3. TSA with MB glenoid?
4. RSA?
5. Others?

Glenoid vault center

and

Perpendicular scapular plane line

1/ Glenoid biconcave type B2?

2/ Type C glenoid?

How do you manage

The posterior defect?

1. Asymmetric reaming of the anterior glenoid?

2. To combine differential anterior glenoid vault reaming and posterior bone graft (MB)?

3. Buttressing the defect with bone cement?

4. Glenoid prostheses augmented with an oblique posterior wedge?

5. Others?

Posterior glenoid bone graft

1. Cortical iliac crest bone?
2. Cancellous bone (HH)?
3. Others?

Rocking Horse effect

… in the horizontal plane…



Matsen FA, Franklin JL, Barret WP, Jackins SE
Glenoid loosening in total shoulder arthroplasty:association withrotator cuff deficiency.
J Arthroplasty 1988; 3: 39

Glenoid type B2: What is the worst prognosis factor?

1. The posterior subluxation of the humeral head?
2. The posterior erosion?
3. Others?

Glenoid type B2:

How do you manage the Posterior subluxation?

1. Anteverting the humeral component?
2. Doesn't matter?
3. Others?

What are your main complications?

How do you manage them?

1. Posterior instability?
2. Anterior instability?
3. Glenoid loosening?
4. Subscap tear?
5. Others?